KK Women's and Children's Hospital
SingHealth

SINGHEALTH FAMILY MEDICINE SYMPOSIUM 2019

Paediatric Dermatology – Common Pitfalls

Dr. Mark Koh Jean Aan
Head and Senior Consultant, Dermatology Service, KKH
Visiting Consultant, Dept of Dermatology, Singapore General Hospital
Visiting Consultant, Dept of Dermatology, Sengkang General Hospital
Visiting Consultant, National Cancer Center
Adj. Assoc. Prof ., Duke-NUS Graduate Medical School, Paediatric ACP
Adj. Assoc. Prof., Lee Kong Chian School of Medicine, NTU
Senior Clinical Lecturer, Yong Loo Lin School of Medicine, NUS

Agenda

1. Atopic dermatitis and other eczemas
2. Common skin infections and infestations
3. Vascular lesions in children

Case 1

6-month-old, mild, flexural , eczema since 3 months of age. What would you treat?

A) Moisturisers and topical corticosteroids
B) Oral cephalexin
C) Oral prednisolone
D) Oral ciclosporin
E) Food allergy tests

Case 1. 6-month-old, mild, flexural, eczema since 3 months of age. What would you treat?

Moisturisers and topical corticosteroids

Oral cephalexin

Oral prednisolone

Oral ciclosporin

Food allergy tests

Case 1

6-month-old, mild, flexural , eczema since 3 months of age. What would you treat?

A) Moisturisers and topical corticosteroids
B) Oral cephalexin
C) Oral prednisolone
D) Oral ciclosporin
E) Food allergy tests

Case 2

3-year-old, recurrent, itchy, weepy, discoid lesions for last 1 year. How would you treat?

A) Topical corticosteroids and topical antibiotics (e.g. Bactroban)
B) Combination topical corticosteroids with antibiotics (e.g. Fucicort)
C) Oral anti-histamines alone
D) Phototherapy
E) Oral loratadine

KK Women's and Children's Hospital
SingHealth

Case 2. 3-year-old, recurrent, itchy, weepy, discoid lesions for last 1 year. How would you treat?

Topical corticosteroids and topical antibiotics (e.g. Bactroban)

Combination topical corticosteroids with antibiotics (e.g. Fucicort)

Oral anti-histamines alone

Phototherapy

Oral loratadine

Case 2

3-year-old, recurrent, itchy, weepy, discoid lesions for last 1 year. How would you treat?

A) Topical corticosteroids and topical antibiotics (e.g. Bactroban)
B) Combination topical corticosteroids with antibiotics (e.g. Fucicort)
C) Oral anti-histamines alone
D) Phototherapy
E) Oral loratadine

KK Women's and Children's Hospital
SingHealth

AD - Disease Burden

- High prevalence in Singapore:
  - 20.6% in children and adolescents
- Increasing **severity** & **chronicity**
- Many patients have family or personal history of atopy
- Onset most common in infancy
- 60% begins in 1st year of life, 85% by 5 years
- Most will improve before school-age
- 10% of childhood eczema persist or recur in adulthood

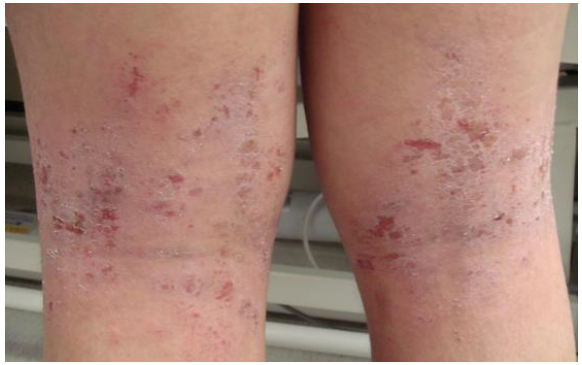

Clinical Features - Infantile Phase

Clinical Features - Infantile Phase

Clinical Features - Infantile Phase

Clinical Features - Infantile Phase

Clinical Features - Childhood Phase

Acute / subacute

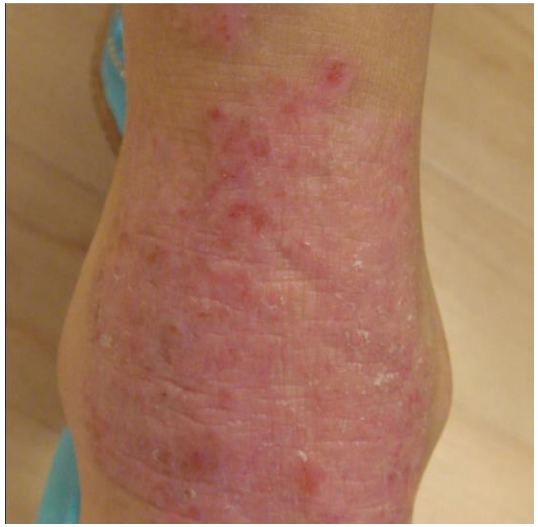

Chronic

Clinical Features - Adolescent Phase

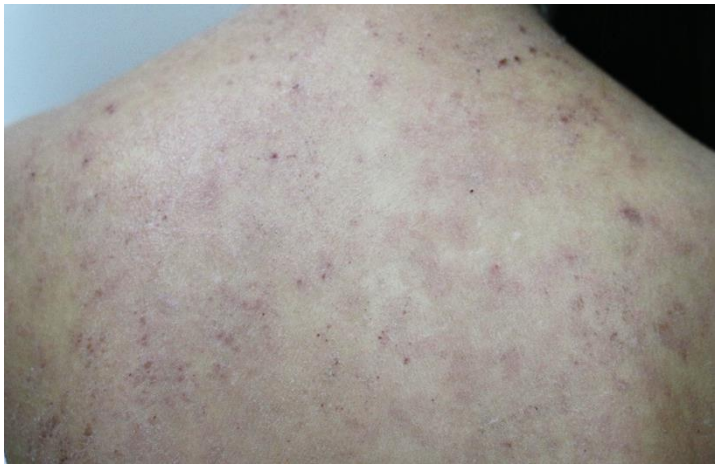

Atopic Dermatitis – Asian Phenotype

Secondary Staphylococcal Infection

Eczema herpeticum

Eczema coxsackium

Molluscum contagiosum

Clinical Features - Other Forms of Eczema in AD Patients

Discoid Eczema

Clinical Features - Other Forms of Eczema in AD Patients

Prurigo Nodularis

Clinical Features - Other Forms of Eczema in AD Patients

Lichen Simplex Chronicus

Clinical Features - Other Skin Manifestations in AD Patients

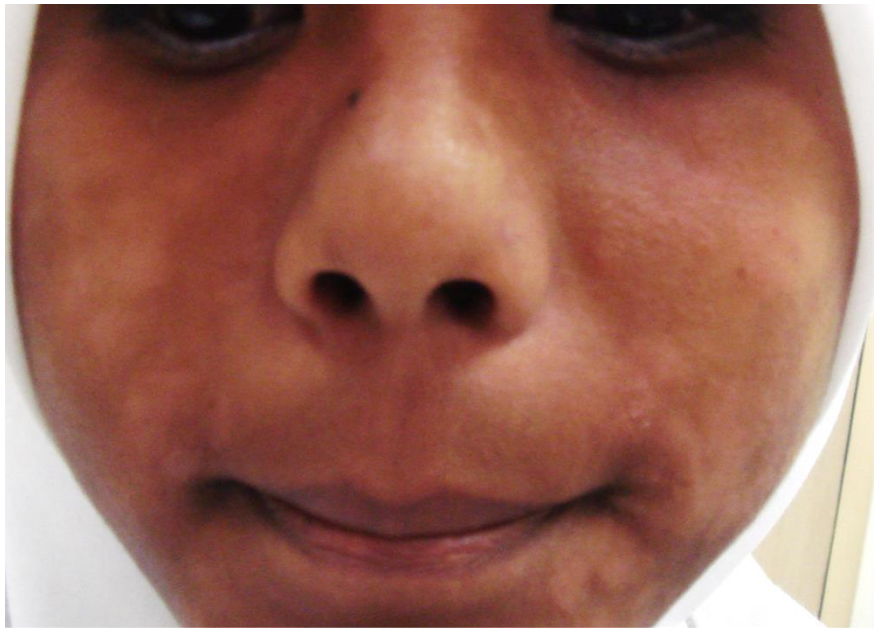

Pityriasis Alba

Association With Food Allergies

- Association of AD and food allergies uncommon:
  - AD: Type IV hypersensitivity
  - Food allergies: Type I hypersensitivity
- Some infantile AD may be a/w food allergies
  - Cow's milk, eggs, wheat, soy
  - Red flags:
    - Extensive, recalcitrant AD
    - Failure-to-thrive
    - GI symptoms
  - Investigations:
    - Skin prick tests
    - Specific IgE (RAST)

Treatment:
Avoidance / Anticipation of Trigger Factors

- Environmental:
  - Changes in climate, heat, sweating
  - House dust mites / dusty environments
  - Strong soaps (e.g. Dettol), detergents, bubble baths
  - Pets, carpets, stuff toys
- Infections
- Vaccinations
- Arthropod bites
- Stress
- Scratching

Treatment: Daily Dry Skin Care

- Daily short showers or baths with cool or slightly warm water
- Mild soap or soap substitute

Treatment: Moisturisers

- Apply 2-3 times daily
- Ointments > Creams > Lotions
- Apply even during quiescent periods
- Aids in restoring impaired epidermal barrier function
- Improves / prevents / minimize eczema

Daily Dry Skin Care: Moisturisers

- Common queries on the use of moisturisers:
  - What is the best moisturiser?
    - One that patient will apply frequently on a daily basis
    - One that works for the patient
    - One that is affordable
  - Where should moisturisers be applied?
    - Whole body
  - When should moisturisers be applied?
    - Shortly after a bath / shower
    - After applying steroid creams on the red/itchy/bumpy areas

Treatment – Topical Steroids

- Topical Corticosteroids:
  - Mainstay of treatment for patients with atopic dermatitis
  - Different potencies available:
    - Age
    - Site of eczema
    - Severity of eczema
  - Ointments vs. Creams:
    - Ointments:
      - More occlusive (more potent), less potential for irritancy
      - More sticky & messy, poorer patient compliance
    - Creams:
      - Less sticky and messy, better patient compliance
      - Less occlusive (less potent), more potential for irritancy

Treatment – Topical Steroids

- Neonates / young infants:
  - Low-to-mid potency
  - E.g. Hydrocortisone, desonide, ¼ str betamethasone

Treatment – Topical Steroids

- Older infants and children:
  - Face and flexures:
    - Low- to mid- potency
    - E.g. Desonide cream 0.05%, Betamethasone 0.025%,

Treatment – Topical Steroids

- Older infants and children:
  - Trunk and limbs:
    - High-potency
    - E.g. Betamethasone 0.1% cream or ointment, Elomet (Mometasone 0.1%)

Treatment – Topical Steroids

- If signs of secondary bacterial infection:
  - Topical steroid + topical antibiotic
  - E.g. Fucicort@, betamethasone/vioform

Topical Steroids - Practical Tips

- “Hit hard and get out quick”
- Advise patients to apply till eczematous skin is “not red, not itchy and smooth / flat”
- If giving potent / superpotent topical steroid, give a earlier review to reduce strength of steroids when skin improves
- Avoid too many creams or too confusing regimens
- Start with cream-based topicals unless skin is very irritated or very dry, then switch to ointment-based topicals
- If creams are too stinging / burning / painful, switch to ointment-based topicals
- Use lotions for scalp eczema

Treatment – Calcineurin Inhibitors

- Pimecrolimus cream
  - < 2 years of age
- Tacrolimus ointment
  - 2-8 years: 0.03%
  - > 8 years: 0.1%
- Side effects:
  - Irritation, burning

Treatment – Anti-histamines

- Itch in AD not mediated solely by histamine
- Main benefit from the use of anti-histamines is for sedative effect
- Use of sedating anti-histamines at bedtime most beneficial
- Side-effect: Daytime somnolence
- Sedating anti-histamines:
  - Hydroxyzine
  - Chlorpheniramine
  - Doxepin
  - Mirtazipine

Treatment – Staph. Infection

- Acute treatment:
  - Anti-bacterial soaks / soaps:
    - Potassium permanganate (PP) / normal saline soaks
  - Topical steroid + topical antibiotic e.g. Fucicort
  - Oral antibiotics:
    - Cephalexin or cloxacillin 50 mg/kg/day for 7-14 days
    - Erythromycin or clindamycin, if allergic to penicillins

Treatment of Severe AD

- Phototherapy
- Immunosuppressives
  - Ciclosporin
  - Azathioprine
  - Methotrexate
- Biologics
  - Dupilumab

KK Women's and Children's Hospital
SingHealth

CASE 3

3 year old with these slightly pruritic lesions, spreading over the last 2 weeks. How would you treat the patient?

A) Topical antifungals
B) Topical acyclovir
C) Topical corticosteroids
D) Oral cephalexin
E) Oral prednisolone

Case 3. 3 year old with these slightly pruritic lesions, spreading over the last 2 weeks. How would you treat the patient?

Topical antifungals

Topical acyclovir

Topical corticosteroids

Oral cephalexin

Oral prednisolone

CASE 3

3 year old with these slightly pruritic lesions, spreading over the last 2 weeks. How would you treat the patient?

A) Topical antifungals
B) Topical acyclovir
C) Topical corticosteroids
D) Oral cephalexin
E) Oral prednisolone

Impetigo

- **Clinically:**
  - Can involve any body surface area
  - Most common on exposed areas, especially face, hands, neck, extremities
  - May have fever, lymphadenopathy

Impetigo

1. Non-bullous impetigo:

- More common (70%) than bullous form
- Often begins as a pustule or erythematous papule
- Overlying honey-crusted scales
- Can be caused by *Staph. aureus* or Grp A β-haemolytic streptococci or mixed

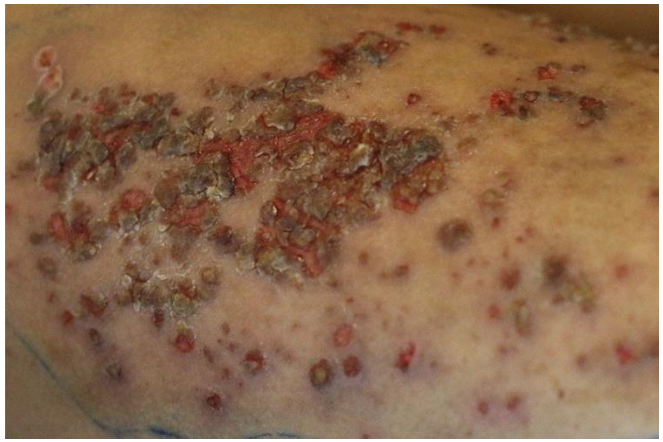

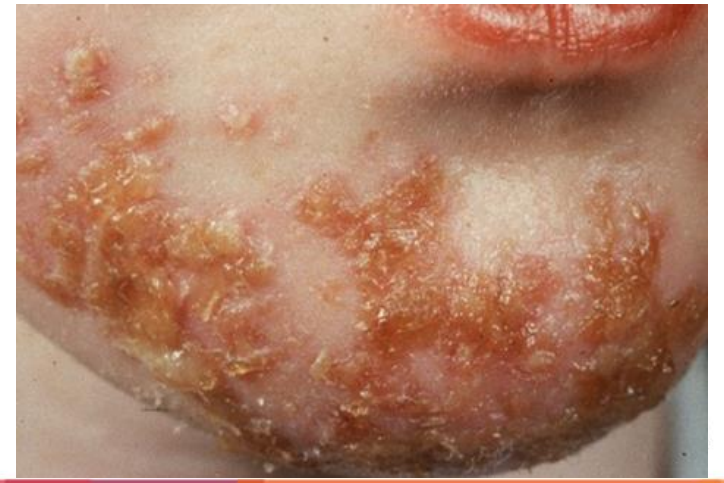

Impetigo

2. Bullous impetigo:

- Less common (30%) than non-bullous form
- Flaccid, thin-walled bullae that rupture easily
- Shallow erosions with peripheral scale (remnant of blister roof)
- *Staph. aureus*

KK Women's and Children's Hospital
SingHealth

Impetigo

- **Treatment:**
  - Topical antibiotics:
    - Fusidic acid, mupirocin, retapamulin
    - Tetracycline, bacitracin, polymyxin, gentamicin, erythromycin
  - Compresses:
    - Potassium permanganate, normal saline
  - Oral antibiotics:
    - Cephalexin, cloxacillin/dicloxacillin, amoxicillin/clavulanic acid
    - Erythromycin, clindamycin, clarithromycin, azithromycin

Case 4

12 year old girl with these painful lesions on right foot for 2 months:

How would you treat her?

A) Cryotherapy
B) Salicylic acid
C) Duct tape occlusion
D) Ablative lasers
E) All of the above

Case 4. 12 year old girl with these painful lesions on right foot for 2 months:

Cryotherapy

Salicylic acid

Duct tape occlusion

Ablative lasers

All of the above

Case 4

12 year old girl with these painful lesions on right foot for 2 months:

How would you treat her?

A) Cryotherapy
B) Salicylic acid
C) Duct tape occlusion
D) Ablative lasers
E) All of the above

Viral Warts

- Caused by HPV
- Common in children, adolescents, adults
- Commonest on the hands and feet
- May be painful, bleed
- Spread by prolonged direct contact, formites

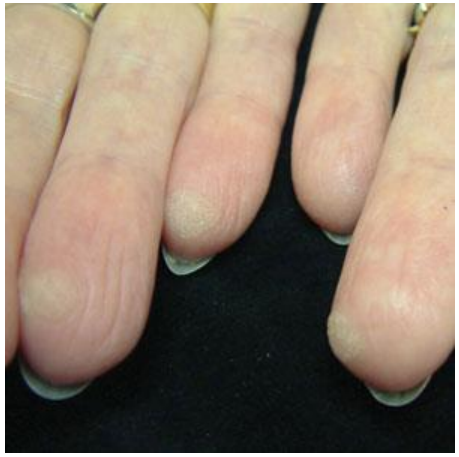

Viral Warts

- Treatment:
  - Topicals:
    - Duofilm (Salicylic acid + Lactic acid)
    - Verrumal (5-FU + Salicylic acid)
    - +/- occlusion with duct tape
  - Destructive:
    - Cryotherapy
    - Electrocautery
    - CO_2 laser

Case 5

5 year old boy with these asymptomatic lesions for 2 months.

What is your diagnosis?

A) Chicken pox

B) HFMD

C) Molluscum

D) Folliculitis

E) Impetigo

Case 5. 5 year old boy with these asymptomatic lesions for 2 months. What is your diagnosis?

Chicken pox

HFMD

Molluscum

Folliculitis

Impetigo

Case 5

5 year old boy with these asymptomatic lesions for 2 months.

What is your diagnosis?

A) Chicken pox

B) HFMD

C) Molluscum

D) Folliculitis

E) Impetigo

Molluscum Contagiosum

- Poxvirus
- Very common in children
- Spread by direct contact

Molluscum Contagiosum

- Treatment:
  - Observation
  - Topicals: Imiquimod, tretinoin cream
  - Liquid nitrogen, curettage, prick & express
  - Electrocautery
  - Cantharidin

CASE 6

3 year old child with very itchy rash for the past 2 months. Grandfather also has itchy rash. How would you treat the patient?

A) Topical malathion
B) Oral cephalexin
C) Potent topical steroids
D) Oral anti-histamines
E) Topical miconazole

Case 6. 3 year old child with very itchy rash for the past 2 months. Grandfather also has itchy rash. How would you treat the patient?

Topical malathion

Oral cephalexin

Potent topical steroids

Oral anti-histamines

Topical miconazole

CASE 6

3 year old child with very itchy rash for the past 2 months. Grandfather also has itchy rash. How would you treat the patient?

A) Topical malathion
B) Oral cephalexin
C) Potent topical steroids
D) Oral anti-histamines
E) Topical miconazole

Scabies

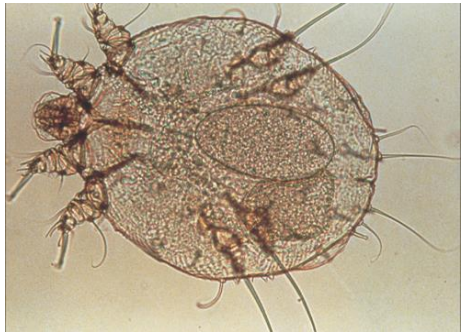

- Caused by mite *Sarcoptes scabeii*
- Spread by prolonged direct contact
- Very itchy, especially at nights

Scabies

- **Treatment:**
  - Topical malathion (> 1 yr old, apply neck down, leave 24 hr)
  - Topical permethrin (< 1yr old, apply whole body, leave overnight)
  - Need to **repeat after 1 week**
  - Need to treat **whole family** (including domestic help, grandparents)
  - Need to inform school / childcare
  - Wash all bedding

CASE 7

2.5 month old child with enlarging lesion on the face since 1 month of age. Was not present at birth.

What treatment is required?

A) Observation for self involution
B) Topical timolol
C) Oral propranolol
D) Oral antibiotics
E) Topical steroids

Case 7. 2.5 month old child with enlarging lesion on the face since 1 month of age. Was not present at birth. What treatment is required?

Observation for self involution

Topical timolol

Oral propranolol

Oral antibiotics

Topical steroids

CASE 7

2.5 month old child with enlarging lesion on the face since 1 month of age. Was not present at birth.

What treatment is required?

A) Observation for self involution
B) Topical timolol
C) Oral propranolol
D) Oral antibiotics
E) Topical steroids

Infantile Haemangiomas

- Older terms: Strawberry, cavernous, capillary haemangioma
- Commonest benign soft tissue tumour of childhood
- 2-4% of newborns

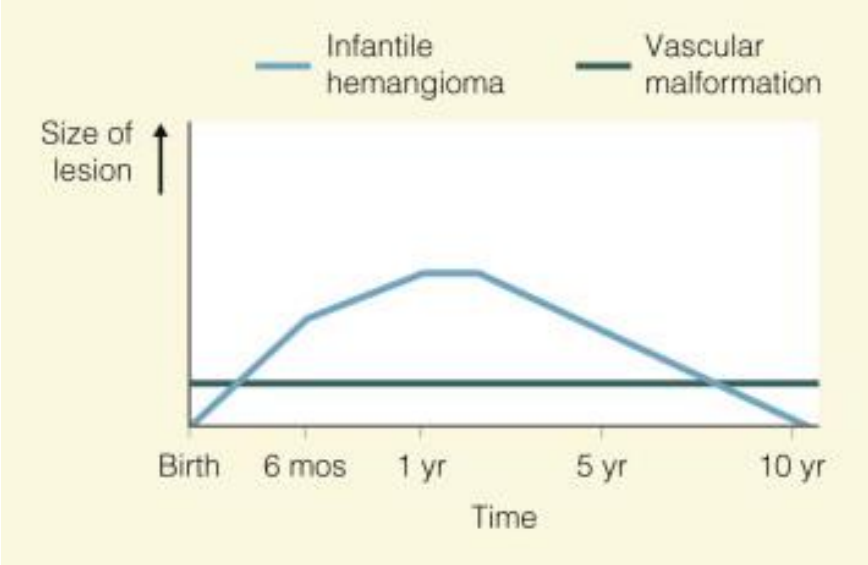

Infantile Haemangiomas

Superficial haemangioma

Deep haemangioma

Mixed haemangioma

PHACES Syndrome

P – Posterior fossa abnormalities (Dandy-Walker and/or cerebellar hypoplasia or dysgenesis)

H – Hemangioma (segmental)

A – Arterial abnormalities (Intra or extra-cranial)

C – Cardiac defects (mostly aortic coarctation)

E – Eye abnormalities

S – Sternal cleft and supra-umbilical raphe

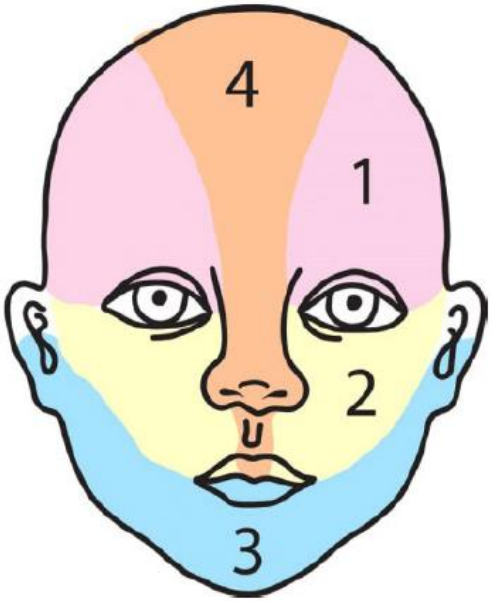

Fig. 2. Proposed segment map (reproduced with permission from Haggstrom et al., in press). [Color figure can be viewed in the online issue, which is available at www.interscience.wiley.com.]

PELVIS Syndrome

Perineal hemangioma
External genital malformation
Lipomyelomeningocoele
Vesicorenal abnormalities
Imperforate anus
Skin tag

Complications

- **Impairment of function**
  - **Periorbital**: Eye complications e.g. astigmatism, visual axis obstruction, strabismus
  - **Peri-oral**: Feeding difficulties
  - **"Beard"** distribution: Risk for upper airway & subglottic IH
  - **Ulcerated** peri-anal: Damage anal sphincter, incontinence
  - **Large facial**: Severe disfigurement




KK Women's and Children's Hospital
SingHealth

Treatment: Propranolol

Christine Léauté-Labrèze, M.D.
Eric Dumas de la Roque, M.D.
Thomas Hubiche, M.D.
Franck Boralevi, M.D., Ph.D.
Bordeaux Children's Hospital

N ENGL J MED 358;24 WWW.NEJM.ORG JUNE 12, 2008

Propranolol for Severe Hemangiomas of Infancy

TO THE EDITOR: Despite their self-limited course, infantile capillary hemangiomas can impair vital or sensory functions or cause disfigurement. Corticosteroids are the first line of treatment for problematic infantile capillary hemangiomas[1,2]; other options include interferon alfa[3] and vincristine.[1] We have observed that propranolol can inhibit the growth of these hemangiomas. Our preliminary data from 11 children are summarized in Table 1 in the Supplementary Appendix, available with the full text of this letter at www.nejm.org.

The first child had a nasal capillary hemangioma. Despite corticosteroid treatment, the lesion was stabilized but obstructive hypertrophic myocardiopathy developed, so the patient was treated with propranolol. The day after the initiation of treatment, the hemangioma changed from intense red to purple, and it softened. The corticosteroids were tapered, but the hemangioma continued to improve. When the corticosteroids were discontinued, no regrowth of the hemangioma was noted. When the child was 14 months of age, the hemangioma was completely flat.

The second child had a plaque-like infantile capillary hemangioma involving the entire right upper limb and part of the face (Fig. 1). At 1 month of age, a subcutaneous component developed, and despite corticosteroid treatment, the hemangioma continued to enlarge. Magnetic resonance imaging revealed intraconal and extraconal orbital involvement, as well as an intracervical mass causing compression and tracheal and esophageal deviation (see the Supplementary Appendix). Ultrasonography showed increased cardiac output, and treatment with propranolol, at a dose of 2 mg per kilogram of body weight per day, was initiated. Seven days later, the child was able to open his eye spontaneously, and the mass near the parotid gland was considerably reduced in size. Prednisolone was discontinued at 4 months of age, without any regrowth of the hemangioma; at 9 months of age, the eye opening was satisfactory, and no major visual impairment was noted.

After written informed consent had been obtained from the parents, propranolol was given to nine additional children who had severe or disfiguring infantile capillary hemangiomas (see Table 1 in the Supplementary Appendix). In all patients, 24 hours after the initiation of treatment, we observed a change in the hemangioma from intense red to purple; this change was associated with a palpable softening of the lesion. After these initial changes, the hemangiomas continued to improve until they were nearly flat, with residual skin telangiectasias. Ultrasound examinations in five patients showed an objective regression in thickness associated with an increase in the resistive index of vascularization of the hemangioma (Table 1 in the Supplementary Appendix).

3 mth →

6 mth →

3 mth →

3 mth →

1 mth →

2 mths →

2 mths →

Propranolol – What Have We Learnt?

- **Earlier** treatment (before 6 mth) → better results
- Optimal dose: **2-3** mg / kg / day
- Duration: Till **1 yr** of age or at least **6 months**
- < 10% poor response, < 10% recurrence
- Outpatient monitoring:
  - Baseline HR, BP, ECG
  - Monitor with BP and HR hourly for 2 hr
- Inpatient monitoring:
  - Cases with co-morbidities (e.g. PHACES)
  - Very young neonates < 30 days

Tan JMC et al., Unpublished data from KKH

Topical β-blockers - Timolol

Topical Timolol Gel for Infantile Hemangiomas: A Pilot Study

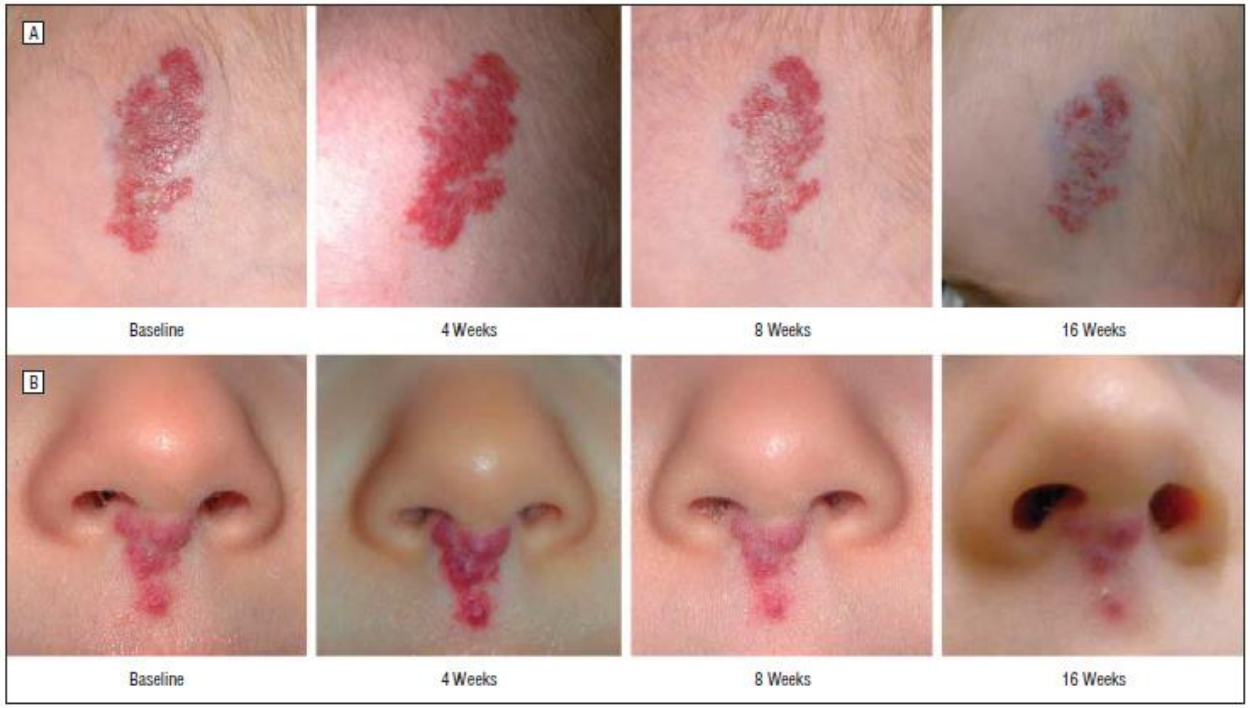

Figure 1. Regression of infantile hemangiomas over time in 2 patients. A, Four-month-old patient with a left forehead hemangioma. B, A 14-month-old patient with a philtrum hemangioma.

Pope and Chakkittakan, 2010

Topical Timolol – KKH Experience

3 months →

10 months →

KK Women's and Children's Hospital
SingHealth

Topical Timolol – KKH Experience

1 month →

8 month →

KK Women's and Children's Hospital
SingHealth

Topical Timolol – What Have We Learnt?

- Better outcomes:
  - **Thinner** lesions
  - **Early** treatment
- Treat for at least **6 months** or until **1 year of age**
- No major adverse complications, no need for monitoring
- Recommendations:
  - **Non-critical** IH (non-life and function threatening)
  - Parents not comfortable with treatment with systemic β-blockers

Ng MSY et al., Pediatr Dermatol 2017;34:492-493

Conclusion

- Atopic dermatitis, skin infections and vascular anomalies are common skin conditions in children and can present to primary care doctors
- History and clinical examination are important in the diagnosis of these conditions
- Most of these cases can be treated in the primary care setting
- Cases that have unusual presentation, difficult or recalcitrant to treatment or severe require referral to paediatric dermatologist

Thank You

Dermatology Service, KKH

KK Women's and Children's Hospital
SingHealth

KKH Paediatric Dermatology @ Sengkang General Hospital (SKH)

KK Women's and Children's Hospital
SingHealth

KK Women's and Children's Hospital
SingHealth

Paediatric Dermatology Workshop

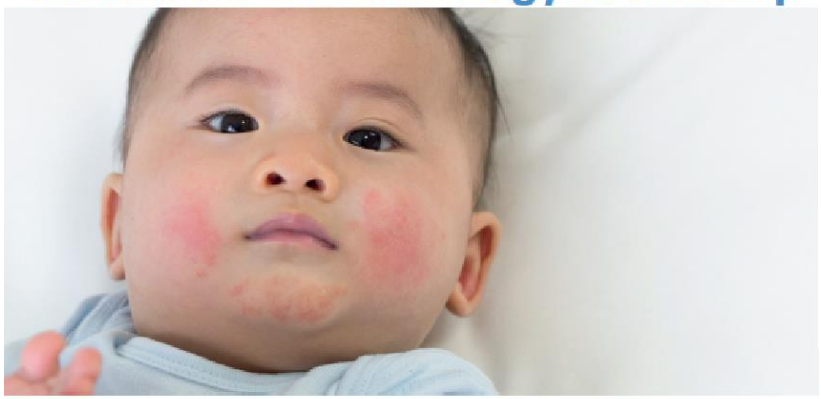

Date : **24 August 2019 (Saturday)**

Day 1: Main Workshop
1.30pm to 5.30pm

Optional Workshops

Paediatric Dermatology 101 for Residents Workshop
9.00am to 12.30pm

Nursing 101 Workshop
10.00am to 12.00pm

Date : **25 August 2019 (Sunday)**

Day 2: Main Workshop
8.45am to 12.15pm

Venue : **KKH Auditorium, (Training Centre), Level 1, Women's Tower**

Fee : **$15 per participant** (Main Workshop)
$10 per participant (Resident 101 or Nursing Workshop)
Free Admission for all SingHealth staff/ trainees/ residents/ DSS and SPS members

SNB-CPE / CME points will be awarded.

PATIENTS. AT THE HEART OF ALL WE DO.

Main Workshop - Day 1, 24 August 2019 (Saturday)

Time	Topic
12.30pm	**Registration and lunch**
1.30pm	**Welcome address**
1.35pm	**Quiz time 1**
1.45pm	**Atopic dermatitis – What is new?** Dr Lee Hwee Chyen Associate Consultant Dermatology Service, KKH
2.15pm	**Food: What to avoid in eczema** Dr Loh Wenyin Consultant Allergy Service, KKH
2.45pm	**Approach to a child with persistent dermatitis** Dr Emily Gan Consultant Dermatology Service, KKH
3.15pm	**Tea break**
3.45pm	**Newborn rashes** Dr Chong Jin Ho Visiting Consultant Dermatology Service, KKH
4.15pm	**Common skin infections in children** Dr Uma Alagappan Consultant Dermatology Service, KKH
4.45pm	**Approach to a child with a suspected genodermatosis** Assoc Prof Mark Koh Head and Senior Consultant Dermatology Service, KKH
5.15pm	**Quiz time 2**
5.30pm	**End of programme**

Main Workshop - Day 2, 25 August 2019 (Sunday)

Time	Topic
8.00am	**Registration and breakfast**
8.45am	**Welcome address**
8.50am	**Quiz time 3**
9.00am	**Common hair and nail conditions in children** Dr Lucinda Tan Visiting Consultant, Dermatology Service, KKH Senior Consultant, National Skin Centre
9.30am	**Common birthmarks – How to recognise and what not to miss** Dr Ker Khor Jia Visiting Consultant Dermatology Service, KKH
10.00am	**Dermatological urgencies and emergencies in children** Dr Sharon Wong Consultant Dermatology Service and General Paediatrics Service, KKH
10.30am	**Tea break**
11.00am	**Approach to urticarial rashes in children** Dr Liew Hui Min Visiting Consultant Dermatology Service, KKH
11.30am	**Approach to travel-related dermatoses in children** Dr Colin Tan Resident Physician Dermatology Service, KKH
12.00pm	**Quiz time 4**
12.15pm	**End of programme**

Optional Workshops - 24 August 2019 (Saturday)

Paediatric Dermatology 101 for Residents Workshop

Time	Topic
8.00am	**Registration**
9.00am	**Interesting cases from the Genodermatoses Clinic** Dr Madeline Ho Visiting Consultant, Dermatology Service, KKH Senior Consultant, National Skin Centre
9.45am	**Interesting cases from the Vascular Anomalies Clinic** Dr Lynette Wee Associate Consultant Dermatology Service and General Paediatrics Service, KKH
10.30am	**Tea break**
11.00am	**Interesting cases from the Neonatal ICU and nursery** Dr Priya Bishnoi Clinical Associate Dermatology Service, KKH
11.45am	**Interesting cases from the paediatric wards** Dr Valerie Ho Associate Consultant Dermatology Service and General Paediatrics Service, KKH
12.30pm	**End of workshop**

Nursing Workshop

Time	Topic
9.30am	**Registration**
10.00am	**Introductory lecture**
10.30am	**Five ands-on practical sessions** • Eczema counselling • Wet wraps/ Double pyjamas • PP/ Saline soaks • Skin scrape for fungal microscopy/ Culture/ Scabies • Liquid nitrogen Ms Florence Ng, Assistant Nurse Clinician, Dermatology Service, KKH Ms Juneideh Jamaloddin, Senior Staff Nurse, Dermatology Service, KKH Ms Serene Oh, Senior Staff Nurse, Dermatology Service, KKH Ms Praveena Suras, Staff Nurse, Dermatology Service, KKH Ms Soh Yoke Teng, Staff Nurse, Dermatology Service, KKH
12.00pm	**End of workshop**

KK Women's and Children's Hospital
SingHealth

PATIENTS. AT THE HEART OF ALL WE DO.

ASIAN SOCIETY OF PAEDIATRIC DERMATOLOGY

www.asianpedderm.com